# The Use of Point of Care Ultrasound in Hand Surgery

Stephanie Marie Bollard, MB, MCh,*‡ Brendan Kelly, MB, BSc, MSc,‡§ Cian McDermott, MD,† Shirley Potter, MD, BSc, PhD*‡

Point of care ultrasound (POCUS) is the use of ultrasound (US) imaging technology by non-sonographer, non-radiologist treating clinicians. Handheld US systems are increasing in popularity and becoming widely available and easily accessible to hand surgeons in clinical practice. Adapting POCUS into the repertoire of the hand surgeon can aid in the diagnosis of many common hand surgery presentations and shorten operative times. In this review, we outline the potential uses and advantages of incorporating POCUS into hand surgery practice incuding its use in emergencies such as trauma, infections, and foreign body localization, as well as elective presentations such as nerve compression, procedural guidance, and anesthesia. Finally, this review outlines the training and curriculum development required to ensure safe implementation of POCUS into a hand surgery practice. *(J Hand Surg Am. 2021;■(■):■−■. Copyright © 2021 by the American Society for Surgery of the Hand. All rights reserved.)*

**Key words** Carpal tunnel, hand surgery, POCUS, tendon injury, trigger finger.

POINT OF CARE ULTRASOUND (POCUS) is a focused ultrasound (US) examination performed by treating clinicians to enhance a traditional physical examination. Although the use of POCUS cannot be considered a replacement for clinical judgment, it can be used at the bedside to help provide an immediate answer for a specific clinical question.

Point of care US was first described in 1990 for its use in common emergency presentations. Because it is a noninvasive, radiation-free, real-time imaging modality, indications for using POCUS have grown exponentially outside the emergency department.

Ultrasound technology has become miniaturized, cheaper, and more widely available. New systems are ultraportable, connect wirelessly to a display device such as a smartphone or tablet, and are capable of recording high-quality images. Some systems have developed artificial intelligence algorithms to provide remote teleguidance for users and secure cloud-based storage.

Most hand surgeons have not yet introduced POCUS into routine clinical practice. When US was performed before surgery by a hand surgeon, the results influenced management in 21% of cases, including making the decision to manage non-operatively, adaptation of the surgical approach, and the choice of anesthesia.[1] Point of care US is also substantially cheaper than alternative imaging such as magnetic resonance imaging.

This review aims to outline potential uses and advantages of incorporating POCUS into hand surgery practice in both the emergency and elective settings.

*From the *Department of Plastic and Reconstructive Surgery, Mater Misericordiae University Hospital, †Emergency Department and the Pillar Centre for Transformative Healthcare, Mater Misericordiae University Hospital, ‡School of Medicine, University College Dublin, and §Department of Radiology, St Vincent's University Hospital, Dublin, Ireland*

Received for publication September 30, 2020; accepted in revised form February 13, 2021.

No benefits in any form have been received or will be received related directly or indirectly to the subject of this article.

**Corresponding author:** Shirley Potter, MD, BSc, PhD, Department of Plastic and Reconstructive Surgery, Mater Misericordiae University Hospital, Eccles Street, Dublin 7, Ireland; e-mail: shirleypotter@mater.ie.

0363-5023/21/■ ■-0001$36.00/0
https://doi.org/10.1016/j.jhsa.2021.02.004

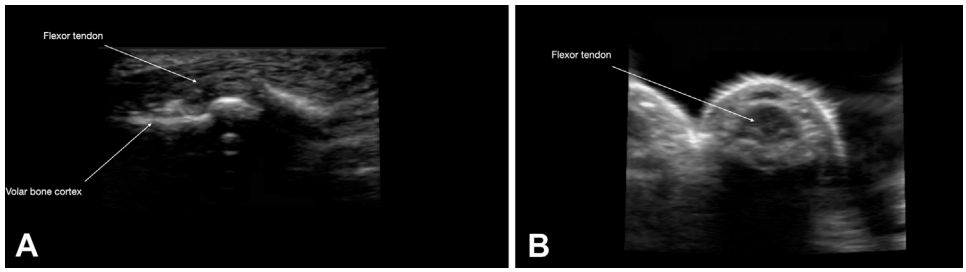


**FIGURE 1: A** Digital flexor tendon in the longitudinal axis. There is a hyperechoic rim of bone in the far field with overlying parallel tendon fibres in the near field. **B** Flexor tendon is shown in short axis as demonstrated by the central hypoechoic area. All US images were generated using a ultraportable handheld device. The images are of lesser quality than would be expected using a larger cart-based system.

## POINT OF CARE US IN EMERGENCY HAND SURGERY

### Assessment of tendon injuries

Point of care US may be used to assess tendon injury, particularly when the clinical examination is limited by pain. In the longitudinal plane, tendons demonstrate a fibrillar pattern of parallel hyperechoic lines on US (Fig. 1A), whereas in transverse, they appear as hyperechoic ovoid structures containing brightly clustered dots (Fig. 1B). A rupture appears as a definite gap in the tendon or an inability to identify the proximal or distal ends, often associated with the formation of intervening hypoechoic hematoma.[2]

Akhavan et al[3] compared the US appearance of tendons with intraoperative pathology and demonstrated a sensitivity and specificity of 100% and 99.4%, respectively, for the diagnosis of tendon lacerations when it was performed by emergency physicians. In cadaveric studies, surgeon-performed US could detect 96.2% of flexor tendon lacerations and could localize the proximal stump in 78% of cases,[4] reducing extensive intraoperative exploration. In closed injuries, sensitivity and specificity were reported to be as high as 95% to 96% and 93% to 95%, respectively, outperforming clinical examination.[5]

Ultrasound can also be used to triage patients with poor outcomes after tendon repair. Features used to identify lacerations acutely may also indicate rupture after surgery, and dynamic examination combined with abnormal peritendinous soft tissue suggests adhesions. Budovec et al[6] reported 100% sensitivity and 93% specificity when US performed by a radiologist was used to diagnose postoperative tendon rupture or adhesive scarring.

### Soft tissue hand infections

In pyogenic tenosynovitis, delays in treatment can have a negative impact on prognosis. Hallmarks of tenosynovitis on US include increased fluid volume in the sheath, seen as a hypoechoic collection around the tendons, improving tendon visualisation.[2] Infective effusions tend to be more echogenic and are often accompanied by thickened and hyperechoic surrounding soft tissue and a thickened synovial sheath, with an increased diameter compared with other digits. Jardin et al[7] report a sensitivity of 94.4% and specificity of 74.4% in equivocal cases; all US studies in the series were performed by operators with variable training. Although this should remain a clinical diagnosis, the use of POCUS in this setting can serve as an adjunctive rule-in test for equivocal cases, aiding earlier diagnosis and quicker initiation of treatment.

Point of care US is also useful in detecting subcutaneous collections. Hematomas and abscesses appear as anechoic or hypoechoic collections disrupting the surrounding normal tissue architecture, resulting in a posterior enhancement artifact. They may have septae and are often compressible. In the case of abscesses, these may have an echogenic irregular capsule and may exhibit swirling upon movement of their contents (Fig. 2). The addition of POCUS is useful in managing soft tissue infections, for which it has the potential to change management in a substantial proportion of cases.[8] In the diagnosis of abscesses, POCUS has a reported sensitivity of 97% and specificity of 83%.[9] It may also be used to guide drainage, aiding targeted aspiration.

### Foreign object localization and removal

Whereas foreign objects that are radiopaque are easily visualized on plain film radiographs, those that are not can be difficult to identify and remove; over a third are missed by the initial treating physician.[10]

Foreign objects appear sonographically as hyperechoic,[8] although they may vary in appearance (Fig. 3). Ultrasound detection of foreign objects has

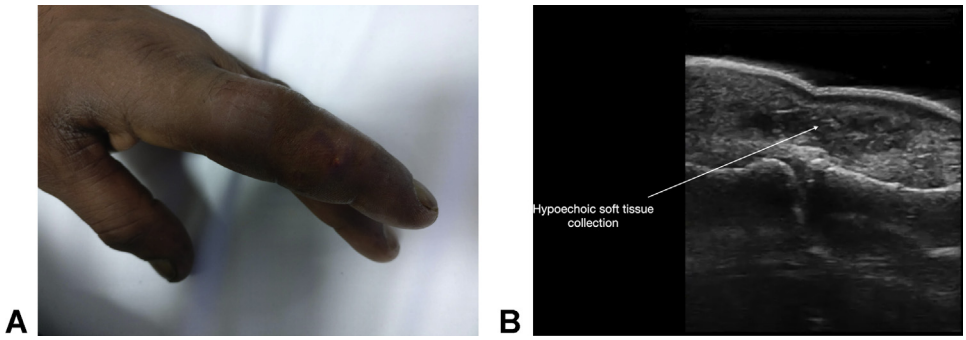


**FIGURE 2:** **A** The left index finger of a patient with erythema and tenderness overlying the middle phalanx. This is likely a soft tissue abscess. **B** Longitudinal view of the same digit shown in (A) demonstrating a hypoechoic collection in the soft tissue overlying the extensor tendon. This supports the diagnosis of an abscess.

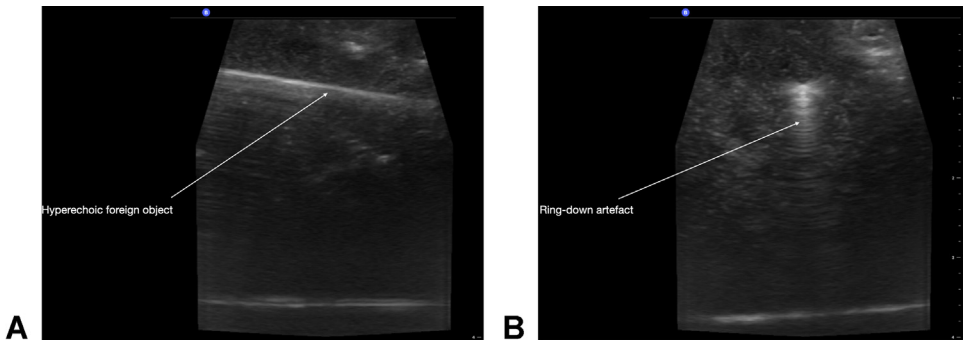


**FIGURE 3:** A metallic foreign object shown in **A** longitudinal and **B** short axis. Note the ring down artifact produced by the metal.

an overall sensitivity and specificity of 72% and 92%, respectively.[11] In the specific case of radiolucent bodies such as wood and plastic, it yields a sensitivity of 96.7%.[11] However, because foreign bodies themselves are heterogenous, these figures must be interpreted with caution. Point of care US can also be used to localize objects during surgery. This can minimize operative time and increase the accuracy of incisions as well as reduce radiation exposure by reducing the use of image intensifiers in the operating room.

Pain is a common presenting symptom in the emergency setting. The placement of a transducer on the skin can exacerbate this, decreasing patient compliance. Use of copious amounts of gel within a transducer sleeve can minimize discomfort by reducing pressure, and applying a transparent dressing over an open wound can also facilitate the US examination. The water bath technique is also useful in this setting.[12] This technique involves placing the extremity in a large flat bath of lukewarm water. The transducer is then placed on or just under the surface of the water above the area of interest without touching it, acting as if it were a conventional gel (Fig. 4). This allows accurate visualization of anatomy, although it may result in an artifact related to spatial resolution of the linear array transducer and the motion artifact of the water bath. This is seen in Figure 4B as the feathered outline of the finger's soft tissue. However, it dramatically reduces discomfort. This technique has the added advantage of reducing near-field dead space, an area of poor image quality just beneath the transducer, improving visualization of superficial foreign bodies. It also allows for dynamic image acquisition, because the patient can move the hand within the water bath.

## POINT OF CARE US IN ELECTIVE HAND SURGERY

### Nerve compressions

Traditional diagnosis of nerve compression syndromes is based on history and examination. However, equivocal cases can be challenging, and nerve conduction studies are often required. Point of care US may prove a useful adjunct in these cases. On US, nerves have a fascicular appearance made of hypoechoic parallel lines separated by hyperechoic bands. On transverse scanning, they have a honeycomb-like appearance[2] (Fig. 5).

In carpal tunnel syndrome, for instance, at the site of compression, the nerve becomes flattened;

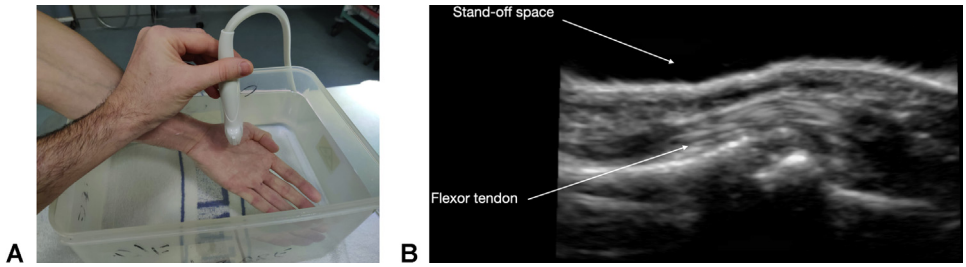


**FIGURE 4: A** Water bath technique. A linear transducer is placed on the surface of the water to increase near-field stand-off zone and allow improved spatial resolution. **B** The same structure as shown in Figure 1(A), but the digit is imaged while immersed in a water bath. Note the anechoic space created by the water that enhances the resolution of the flexor tendon underneath.

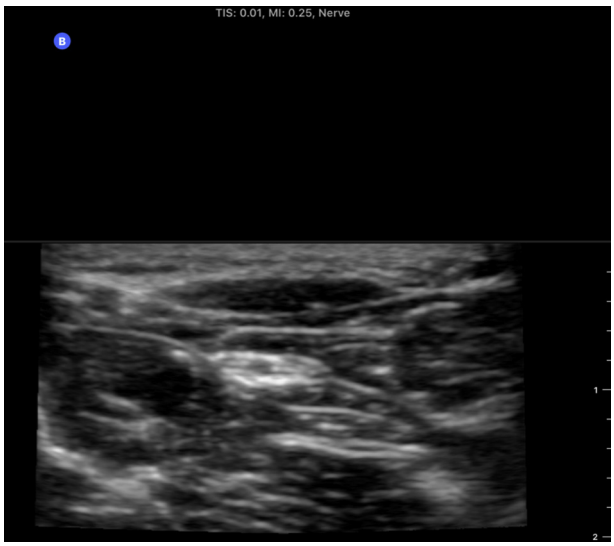


**FIGURE 5:** The median nerve is imaged in the forearm. It appears in the center of the image as a hyperechoic ovoid.

proximally, it becomes swollen owing to vasocongestion. These findings are also visible on US. Many different diagnostic criteria for carpal tunnel syndrome have been described, such as variations in the median nerve cross-sectional area, the absence of nerve movability, and bowing of the flexor retinaculum. In addition, US sensitivity has been reported from 62% to 97.9%, comparable to that of nerve conduction studies at 75% to greater than 85%.[13] With specialized training, this could become a useful adjunct for the hand surgeon, offering a speedy diagnosis in the clinic with a method that is cheaper and more comfortable for the patient compared with nerve conduction studies.

## Procedural guidance

In the clinic, hand surgeons often perform injections for conditions such as de Quervain tenosynovitis or trigger finger. Ultrasound guidance is often not employed in this setting, and injections are performed blindly based on anatomical landmarks and experience.

Ultrasound-guided trigger finger steroid injections ensure the steroid is delivered within the flexor sheath. Current cadaveric studies suggest that accurate injection into the sheath is achieved in only 15% of blind injections for trigger finger, as opposed to 70% accuracy for US-guided placement.[14] It is unclear whether US guidance offers notable clinical benefit, because true intrasheath injection has not been demonstrated to offer a definitive advantage over that outside the sheath. Trials comparing the clinical technique of injecting and US guidance when performed by an experienced radiologist demonstrate no benefit with regard to pain or a decreased need for reinjection.[15]

In the setting of de Quervain tenosynovitis, steroid injections have a variable success rate. Failure of treatment is often attributed to the presence of septations in the first extensor compartment, meaning that the steroid may not come into contact with the extensor pollicis brevis tendon when injected blindly. Direct injection with POCUS guidance may improve this. Studies comparing both blind and US-guided injections demonstrated considerable improvement in symptoms,[16] which suggests that this improved ability to target extensor pollicis brevis can deliver tangible improvement to patients. This use can also be expanded to ensure the targeted delivery of steroid injections to small joint spaces such as the first carpometacarpal joint, or to avoid injection of important structures such as nerves or tendons, in the setting of collagenase injections for Dupuytren disease.

Finally, POCUS can also be used before surgery, in surgical planning, to identify donor tendons and nerves for grafting, and hence to improve accuracy and minimize the size of incisions.

### Regional anesthesia techniques

Regional anesthesia is a useful tool in the elective hand surgery setting. The use of wide-awake anesthesia also saves the patient recovery time and obviates the risk associated with a general anesthetic. The blockade of the median, ulnar, and radial nerves in the forearm can produce total anesthesia of the hand.

Ultrasound-guided nerve blocks, as opposed to traditional landmark-based blocks, have been demonstrated to be more effective when they are used by an experienced operator. This could easily be translated into elective hand surgery practice. After a 1-hour training session, Liebmann et al[17] demonstrated that physicians were able to accomplish these blocks accurately in 9 minutes, and a Cochrane review[18] showed that nerve blocks performed by US guidance provided superior motor and sensory blockade.

## TRAINING, GOVERNANCE, AND QUALITY ASSURANCE

The use of POCUS by clinicians other than radiologists and sonographers has grown exponentially, and formal clinical governance has not kept pace. Ultrasound is well-established as the most user-dependent imaging modality. Importantly, POCUS practice guidelines are being developed by many associations.[19,20] Indeed the Royal College of Radiologists suggests that training of non-radiological medical practitioners should facilitate increased inter-speciality collaboration.

Certain concepts of clinical governance apply in general to any US training. These include, but are not limited to[19,20]:

- Adherence to any national guidelines
- Training in US theory and normal anatomy as well as identification of pathology
- Observed procedures before independent practice
- Recognition of when referral for a second opinion is warranted
- Understanding of the interaction among different imaging modalities

Furthermore, there are other concepts more specific to musculoskeletal US and hand surgery in particular:

- Although US is established as an excellent method of guiding procedures such as joint injections, the importance of referral to an imaging specialist to confirm the diagnosis and evaluate the severity of the condition should not be overlooked.
- Musculoskeletal imaging is perhaps the most inherently multimodal radiologic speciality; different diseases have different manifestations on US, magnetic resonance, computed tomography, and plain film imaging. An awareness of this is paramount to safe practice.

A further important general point is to include the acquired images as well as a written interpretation in patients' medical record. This facilitates communication among different physicians involved in patient care, peer review, education, research, and audit.[21] It reinforces the need for a well-defined scope of practice for POCUS, analogous to the stethoscope as an extension of the physical examination: complementary to, but not replacing, diagnostic US.

## CONCLUSION

Point of care US has increased in accessibility and popularity in recent years and has many potential applications in both emergency and elective hand surgery. Its incorporation into the routine practice of the hand surgeon has the potential to improve preoperative planning, increase the accuracy of diagnosis, and reduce operative times and morbidity. Point of care US also has the potential to improve the allocation of resources. Careful oversight is required to ensure that quality imaging is performed, adequate training is provided, and governance standards are maintained. The wide range of potential applications and subsequent patient benefits suggest that POCUS will have a key role in the future of hand surgery.

## ACKNOWLEDGMENTS

This work was performed within the Irish Clinical Academic Training Programme, supported by the Wellcome Trust and the Health Research Board (Grant No. 203930/B/16/Z), the Health Service Executive National Doctors Training and Planning and the Health and Social Care, Research and Development Division, Northern Ireland.

## REFERENCES

1. Furrer M, Schweizer A, Rufibach K, Meuli-Simmen C. The value of ultrasonography in hand surgery. *Hand (N Y)*. 2009;4(4):385–390.
2. Martinoli C, Bianchi S, M'Hamed D, Pugliese F, Bianchi-Zamorani MP, Valle M. Ultrasound of tendons and nerves. *Eur Radiol*. 2002;12(1):44–55.
3. Akhavan R, Bolvardi E, Pezeshki-Rad M, Abbasi B. Diagnosing hand and wrist tendon injuries in patients with questionable physical findings: let POCUS show its true mettle. *Trauma Monthly*. 2019;24(4):1–5.
4. Ravnic DJ, Galiano RD, Bodavula V, Friedman DW, Flores RL. Diagnosis and localisation of flexor tendon injuries by surgeon-

performed ultrasound: a cadaveric study. *J Plast Reconstr Aesthet Surg*. 2011;64(2):234–239.
5. Gilleard O, Silver D, Ahmad Z, Devaraj VS. The accuracy of ultrasound in evaluating closed flexor tendon ruptures. *Eur J Plast Surg*. 2010;33(2):71–74.
6. Budovec JJ, Sudakoff GS, Dzwierzynski WW, Matloub HS, Sanger JR. Sonographic differentiation of digital tendon rupture from adhesive scarring after primary surgical repair. *J Hand Surg Am*. 2006;31(4):524–529.
7. Jardin E, Delord M, Aubry S, Loisel F, Obert L. Usefulness of ultrasound for the diagnosis of pyogenic flexor tenosynovitis: a prospective single-center study of 57 cases. *Hand Surg Rehabil*. 2018;37(2):95–98.
8. Tayal VS, Hasan N, Norton HJ, Tomaszewski CA. The effect of soft-tissue ultrasound on the management of cellulitis in the emergency department. *Acad Emerg Med*. 2006;13(4):384–388.
9. Subramaniam S, Bober J, Chao J, Zehtabchi S. Point-of-care ultrasound for diagnosis of abscess in skin and soft tissue infections. *Acad Emerg Med*. 2016;23(11):1298–1306.
10. Anderson MA, Newmeyer WL III, Kilgore ES Jr. Diagnosis and treatment of retained foreign bodies in the hand. *Am J Surg*. 1982;144(1):63–67.
11. Davis J, Czerniski B, Au A, Adhikari S, Farrell I, Matthew Fields J. Diagnostic accuracy of ultrasonography in retained soft tissue foreign bodies: a systematic review and meta-analysis. *Acad Emerg Med*. 2015;22(7):777–787.
12. Krishnamurthy R, Yoo JH, Thapa M, Callahan MJ. Water-bath method for sonographic evaluation of superficial structures of the extremities in children. *Pediatr Radiol*. 2013;43(suppl 1):41–47.
13. McDonagh C, Alexander M, Kane D. The role of ultrasound in the diagnosis and management of carpal tunnel syndrome: a new paradigm. *Rheumatology*. 2015;54(1):9–19.
14. Lee D-H, Han S-B, Park J-W, Lee S-H, Kim K-W, Jeong W-K. Sonographically guided tendon sheath injections are more accurate than blind injections. *J Ultrasound Med*. 2011;30(2):197–203.
15. Cecen GS, Gulabi D, Saglam F, Tanju NU, Bekler HI. Corticosteroid injection for trigger finger: blinded or ultrasound-guided injection? *Arch Orthop Trauma Surg*. 2015;135(1):125–131.
16. McDermott JD, Ilyas AM, Nazarian LN, Leinberry CF. Ultrasound-guided injections for de Quervain's tenosynovitis. *Clin Orthop Relat Res*. 2012;470(7):1925–1931.
17. Liebmann O, Price D, Mills C, et al. Feasibility of forearm ultrasonography-guided nerve blocks of the radial, ulnar, and median nerves for hand procedures in the emergency department. *Ann Emerg Med*. 2006;48(5):558–562.
18. Lewis SR, Price A, Walker KJ, McGrattan K, Smith AF. Ultrasound guidance for upper and lower limb blocks. *Cochrane Database Syst Rev*. 2015;(9):CD006459.
19. POCUS Practice Guidelines. SPOCUS. https://spocus.org/admin-resources/practice-guidelines/. Accessed June 13, 2020.
20. Board of the Faculty of Clinical Radiology,The Royal College Of Radiologists. Focused ultrasound training standards. https://www.rcr.ac.uk/system/files/publication/field_publication_files/BFCR%2812%2918_focused_training.pdf. Accessed July 28, 2020.
21. Chawla TP, Cresswell M, Dhillon S, et al. Canadian Association of Radiologists Position Statement on Point-of-Care Ultrasound. *Can Assoc Radiol J*. 2019;70(3):219–225.